

# Changes in serum antimüllerian hormone levels in patients 6 and 12 months after endometrioma stripping surgery

Vera Miodrag Kovačević, M.D.,<sup>a</sup> Luka Momir Anđelić, M.D.,<sup>a</sup> and Ana Mitrović Jovanović, M.D., Ph.D.<sup>b</sup>

<sup>a</sup> General Hospital, Department of Obstetrics and Gynaecology, Subotica; and <sup>b</sup> "Narodni Front" Clinics for Gynaecology and Obstetrics, Faculty of Medicine, University of Belgrade, Belgrade, Serbia

**Objective:** To investigate the impact of laparoscopic endometrioma cystectomy on the ovarian reserve and to identify the most important factors that predict the ovarian reserve in patients with endometriomas.

**Design:** Prospective study.

**Settings:** Endoscopy unit of a general hospital.

**Patient(s):** Fifty-four patients with unilateral ( $n = 37$ ) and bilateral endometriomas ( $n = 17$ ).

**Interventions(s):** The serum antimüllerian hormone (AMH) concentration was assessed before surgery and at 6 and 12 months after surgery.

**Main Outcome Measure(s):** The primary outcome was the damage to the ovarian reserve, as assessed by the serum AMH concentration. Secondary end points were the persistence or recovery of ovarian damage after 1 year.

**Result(s):** AMH concentrations decreased after the laparoscopic excision of cystic ovarian endometriomas. Before surgery and at 6 and 12 months after surgery, the concentrations were, respectively 3.07, 1.29, and 1.46 ng/mL. In the unilateral group, the median AMH levels were 3.31, 1.43, and 1.72 ng/mL, and in the bilateral group the levels were 2.55, 0.98, and 0.89 ng/mL. The serum AMH concentrations thus decreased by  $53.27 \pm 38.2\%$  and  $49.43 \pm 38.3\%$  at 6 and 12 months after cystectomy, respectively.

**Conclusion(s):** In patients with endometriomas, the decrease in ovarian reserve occurs immediately after the excision of the endometrioma. Significant predictors of AMH values at 6 and 12 months after surgery include the baseline AMH level, patient age, and bilateral endometriomas. (Fertil Steril® 2018;110:1173–80. Copyright ©2018 The Authors. Published by Elsevier Inc. on behalf of the American Society for Reproductive Medicine. This is an open access article under the CC BY-NC-ND license (<http://creativecommons.org/licenses/by-nc-nd/4.0/>).

El resumen está disponible en Español al final del artículo.

**Key Words:** Endometrioma, laparoscopy, ovarian reserve, antimüllerian hormone

**Discuss:** You can discuss this article with its authors and other readers at <https://www.fertstertdialog.com/users/16110-fertility-and-sterility/posts/36858-25517>

The estimated prevalence of endometriosis among women of reproductive age is as high as 10% (1). According to Meuleman et al., the prevalence of histologically confirmed endometriosis is ~50% in the population of women who suffer from infertility for at least 1 year, despite regular cycles and partners with a normal

semen analysis (2), and it can reach 25%–45% in women who have painful periods (3). As shown in the study by Nissole and Donnez (4), bleeding and cyst formation occurs after the celomic metaplasia of the invaginated ovarian cortex into the endometrial tissue, with fibrotic reactions of the ovarian cortex that surrounds the cysts. Laparoscopy is the

criterion standard treatment for endometriosis, particularly for endometriomas (5). According to a Cochrane Review in 2008, the laparoscopic surgical stripping of endometriomas results in improved outcomes, including lower endometrioma recurrence rates, lower rates of symptom recurrence, and an increase in the spontaneous pregnancy rate in initially subfertile women (6). That Cochrane Review was based on only three studies (7–9). In all of those studies, bipolar coagulation was used for hemostasis, although the safety of this technique in terms of damage to the ovarian reserve was not investigated.

The ovarian reserve comprises two elements: the size of the stock of

Received December 26, 2017; revised July 18, 2018; accepted July 19, 2018.

V.M.K. has nothing to disclose. L.M.A. has nothing to disclose. G.Z.T. has nothing to disclose. A.M.J. has nothing to disclose.

Reprint requests: Ana Mitrović Jovanović, M.D., Ph.D., "Narodni Front" University Clinic for Gynaecology and Obstetrics, Kraljice Natalije 62, 11000 Belgrade, Serbia (E-mail: [anamitrovicjov@gmail.com](mailto:anamitrovicjov@gmail.com)).

Fertility and Sterility® Vol. 110, No. 6, November 2018 0015-0282

Copyright ©2018 The Authors. Published by Elsevier Inc. on behalf of the American Society for Reproductive Medicine. This is an open access article under the CC BY-NC-ND license (<http://creativecommons.org/licenses/by-nc-nd/4.0/>).

<https://doi.org/10.1016/j.fertnstert.2018.07.019>

primordial follicles and the quality of the oocytes (10, 11). Ovarian reserve declines with increasing age, resulting in a decrease in reproductive function (12). Antimüllerian hormone (AMH) is a dimeric glycoprotein hormone that belongs to the transforming growth factor  $\beta$  superfamily. AMH is produced in the granulosa cells from preantral and early antral follicles, does not depend on the menstrual cycle, and has been used as a marker of ovarian reserve (13).

In recent years, an increasing number of papers have been published that confirm unintentional and unwanted damage to the ovarian reserve after the laparoscopic stripping of endometriomas and the use of bipolar coagulation for hemostasis (14–23). On the other hand, other studies did not observe a significant decrease in serum AMH levels 3 months after cystectomy surgery (24), and the recovery of AMH serum values has been observed 3–6 months after cystectomy (25, 26).

The aim of the present study was to investigate the long-term changes in ovarian reserve after the laparoscopic surgical stripping of endometriomas, because researchers have not clearly determined whether serum AMH concentrations recover 6 and 12 months after cystectomy. Furthermore, we sought to identify the most important factors in predicting ovarian reserve after cystectomy in patients with endometriomas.

## MATERIALS AND METHODS

This prospective cohort study was conducted in the General Hospital, Subotica, Serbia, from February 2013 to November 2016. Before enrollment, every patient was diagnosed with unilateral/bilateral endometrioma(s)  $\geq 4$  cm according to two or more transvaginal ultrasound examinations. The inclusion criteria were: women of reproductive age from 18 to 42 year old, with regular menstrual periods ranging from 25 to 35 days, unilateral/bilateral endometriomas without clinical and sonographic suspicion of ovarian carcinoma, and no evidence of any other endocrine disorder, including thyroid dysfunction, hyperprolactinemia, or Cushing syndrome. Exclusion criteria were: any suspicious findings of malignant ovarian disease before ovarian surgery, a histologically unconfirmed diagnosis of an endometrioma, and oral contraceptive or GnRH analogue use within 3 months before surgery. Informed consents were obtained from all patients. The study included 54 women of reproductive age. The study sample was a convenience sample. Patient symptoms included painful periods, chronic pelvic pain, pain during defecation, dyspareunia, abnormal bleeding/spotting, and/or the presence of infertility.

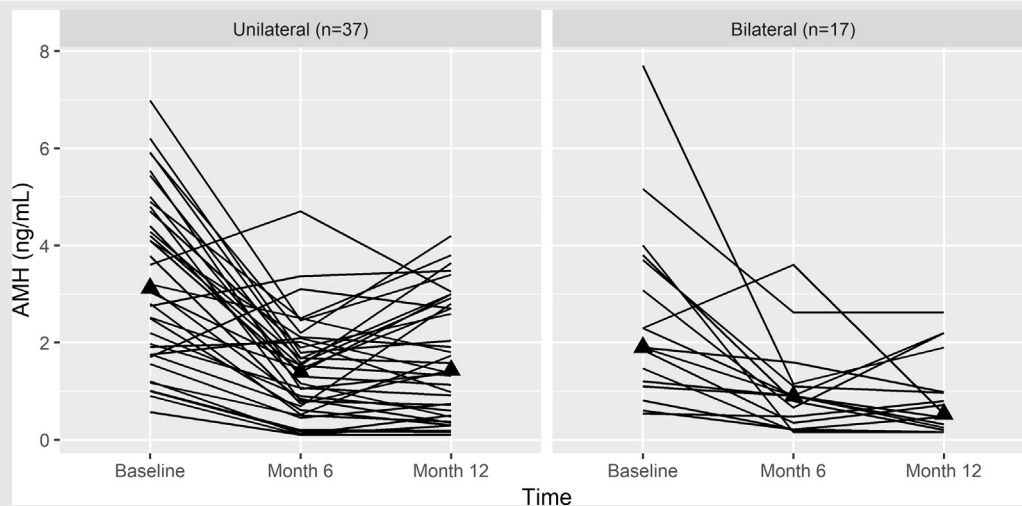
AMH levels were measured in the 54 patients in the early follicular phase of their spontaneous menstrual cycle, from the 3rd to the 5th day before surgery, as well as 6 and 12 months after surgery. AMH levels were determined with the use of the Beckman Coulter AMH Gen II ELISA kit, which provides materials for the quantitative measurement of AMH levels in human serum and lithium heparin-treated plasma. The lowest amount of AMH in a sample that can be detected with 95% probability is 0.08 ng/mL. The intra- and interassay coefficients of variation for AMH levels were 5.3% and 7.7%,

respectively. The FSH test has an analytical sensitivity of  $\sim 0.8$  IU/L. The E<sub>2</sub> ELISA test has an analytical sensitivity of 13 pg/mL of specimen. The percentage change in serum AMH levels was defined as follows:  $100 \times (\text{preoperative AMH level} - \text{postoperative AMH level})/\text{preoperative AMH level}$ .

All operations were performed during the late follicular phase of the menstrual cycle. After a 1.5–2.5-cm subumbilical skin incision was made, a 10-mm trocar was inserted, and pneumoperitoneum was induced by insufflation of carbon dioxide and maintained at a pressure of 12 mm Hg. Then, two additional trocars (5 and 10 mm) were inserted into both supra-inguinal areas under direct laparoscopic observation. Initially, we performed a diagnostic inspection of the pelvis and abdomen to assess the extent of the disease and identify abnormalities or distortions of the pelvic organs. Then we lysed the adhesions and liberated the ovary from its adhesions and from adhesions with surrounding organs, if present. Subsequently, if the endometrioma remained unruptured during adhesion-lysis, we performed an incision of the endometrioma at the antimesenteric site of the affected ovary using bipolar cautery, and the endometrioma was drained by means of aspiration of the chocolate content and further extension of the incision into the antimesenteric edge. After identification of the cleavage plane, the pseudocapsule was stripped from the healthy surrounding normal ovarian tissue with the use of two atraumatic grasping forceps by means of traction and countertraction. In some cases, the identification of the cleavage plane was difficult because the reactive tissue of the endometrioma was strongly adhered to the ovarian tissue. In cases when an endometriotic cyst ruptured during ovarian-lysis and adhesion-lysis, the rupture site on the ovaries was the starting point for cyst enucleation. When necessary, hemostasis was achieved by application of a 30-W current with the use of bipolar forceps on the cyst bed, which was used as little as possible to avoid damaging the normal tissue. No sutures were placed after endometrioma cystectomy. Endometriosis was classified according to the revised American Society for Reproductive Medicine classification scheme (1996). All endometrioma specimens obtained from the operations were submitted for a pathologic examination.

The patients were discharged on the 2nd day after laparoscopy in the absence of adverse events. Immediately after surgery, a GnRH agonist or oral contraceptives (2 mg dienogest + 0.03 mg ethinylestradiol) were continuously administered to 31 and 18 patients, respectively, for the postoperative medical treatment of endometriosis; five patients received no medication. During the last month of postoperative medication, a second-look laparoscopy was recommended to remove residual foci and adhesiolysis; 37 patients underwent a second-look laparoscopy, and 17 patients did not. Six months after the first laparoscopy, on days 3–5 of the first spontaneous menstrual cycle, serum AMH levels were measured; levels were again measured 12 months after the first laparoscopy. In the period between 6 and 12 months after the operation, the patients did not receive any therapy. All operations were performed by the same gynecologist, who had more than 20 years of

FIGURE 1



An individual profile plot of longitudinal antimüllerian hormone (AMH) data obtained from patients with unilateral ( $n = 37$ ) and bilateral ( $n = 17$ ) endometriomas 6 and 12 months after surgery.

Kovačević. Serum AMH levels 12 months after surgery. *Fertil Steril* 2018.

experience in laparoscopic cystectomy. This study was approved by the Ethics Committee at the General Hospital in Subotica on February 8, 2013 (reference no. 01-648/01).

### Statistical Analyses

Descriptive statistics, including the means and standard deviations of continuous variables, percentage changes in repeated measures, and frequency counts of categorical variables, were used to characterize the study sample. Differences in numeric variables between groups and comparisons of the repeated measurements of AMH, FSH, and  $E_2$  levels were analyzed by means of repeated-measures analysis of variance with the use of simple contrasts. Spearman rank correlation coefficient was used to assess the relationships between variables. Multivariate regression models were used to determine predictors of AMH levels at months 6 and 12, whereas linear regression models were applied to determine predictors of the percentage changes in serum AMH levels at month 12. Multivariate regression models included all predictors with  $P$  values  $< .05$  from the univariate analyses. The R environment for statistical computing with ggplot2 package was used to conduct the statistical analyses. The significance level (alpha level) was set to 0.05 (27).

### RESULTS

Fifty-four patients were recruited, 37 (68.5%) of whom had unilateral endometriomas and 17 (31.5%) bilateral endometriomas. The distribution of the diameter of right ovary endometriomas was: 4 cm:  $n = 14$ ; 5–6 cm:  $n = 8$ ; and  $\geq 7$  cm:  $n = 5$ . The distribution of the diameter of left ovary endometriomas was: 4 cm:  $n = 20$ ; 5–6 cm:  $n = 18$ ;

and  $\geq 7$  cm;  $n = 7$ . The mean patient age was  $30.3 \pm 4.5$  years, and all patients had regular menstrual periods. The severity of endometriosis was determined according to the revised American Fertility Society classification, with a mean score of  $49.7 \pm 24.1$ . The mean body mass index was  $21.4 \pm 3.1$  kg/m<sup>2</sup>.

The primary outcome of this study was the damage to the ovarian reserve, as indicated by the serum AMH concentration. Figure 1 presents an individual profile plot of longitudinal AMH data obtained from patients with unilateral ( $n = 37$ ) and bilateral ( $n = 17$ ) endometriomas 6 and 12 months after surgery. Table 1 presents the preoperative and 6- and 12-month postoperative serum AMH levels in the patients with unilateral ( $n = 37$ ) and bilateral ( $n = 17$ ) endometriomas. The mean preoperative, 6-month, and 1-year postoperative serum AMH levels in the unilateral endometrioma group were, respectively,  $3.3 \pm 1.7$ ,  $1.4 \pm 1.0$  ng/mL, and  $1.7 \pm 1.2$ . In the bilateral endometrioma group, the respective values were  $2.5 \pm 1.8$ ,  $0.9 \pm 0.9$ , and  $0.9 \pm 0.8$  ng/mL.

The percentage (relative) changes in the serum AMH levels in the 54 patients recorded at 6 and 12 months after surgery were  $-53.3 \pm 38.2\%$  and  $-49.4 \pm 38.3\%$ , respectively. The percentage changes in the serum AMH levels recorded 6 months after the operation in the unilateral and bilateral endometrioma groups were  $-53.6 \pm 38.4\%$  and  $-52.5 \pm 38.9\%$ , respectively. The percentage changes in the serum AMH levels recorded 12 months after the operation in the unilateral and bilateral endometrioma groups were  $-45.5 \pm 38.9\%$  and  $-58 \pm 36.6\%$ , respectively.

Secondary end points were persistence or recovery of ovarian damage after 1 year. The serum levels of the AMH hormone recovered in the unilateral endometrioma group 12 months after surgery (borderline significant:  $P = .056$ ).

TABLE 1

Preoperative and postoperative (6 and 12 mo) serum antimüllerian hormone levels (ng/mL) in patients with unilateral (n = 37; 68.51%) and bilateral (n = 17; 31.48%) endometriomas.

Endometriosis	Baseline	6 mo	12 mo	Overall P value <sup>a</sup>	P value <sup>b</sup>		
					6 mo vs. baseline	12 mo vs. baseline	12 mo vs. 6 mo
Unilateral (n = 37)	3.31 ± 1.74	1.43 ± 1.01	1.72 ± 1.23	< .001	< .001	< .001	.056
Bilateral (n = 17)	2.55 ± 1.87	0.98 ± 0.91	0.89 ± 0.82	< .001	.003	.001	.698

<sup>a</sup> Repeated-measures analysis of variance.

<sup>b</sup> Paired t test.

Kovačević. Serum AMH levels 12 months after surgery. *Fertil Steril* 2018.

Some recovery of the serum AMH level was observed 12 months after surgery in the bilateral endometrioma group, but the change was not significant ( $P=.698$ ). In 14/54 patients (26%), the decrease in serum AMH levels recorded 12 months after the surgery was not greater than 30%, and the patients were considered to be recovered.

Several univariate analyses were performed to identify factors that were significantly correlated with the percentage change in AMH levels in patients with endometrioma(s). Table 2 presents the results from univariate linear regression analyses in which the rate of decline in serum AMH levels at 12 months after surgery was the dependent variable. In univariate regression models, significant predictors of serum AMH values at 6 and 12 months after surgery were baseline serum AMH levels, patient age, and bilateral endometriomas.

Table 3 presents the results from multivariate regression analyses in which serum AMH levels at 6 and 12 months after surgery were the dependent variables. Of these three predictors of ovarian reserve, the only significantly precise predictor was the baseline serum AMH level. None of the other predictors were associated with a relative decrease in serum AMH level at 12 months after surgery.

Supplemental Table 1 (available online at [www.fertstert.org](http://www.fertstert.org)) presents the Spearman correlation coefficients between age and serum AMH levels and the percentage change in serum AMH levels at 6 and 12 months after the operation

versus baseline levels. A strong negative correlation between AMH levels and women with endometriomas was confirmed at baseline ( $r = -0.32$ ;  $P < .017$ ) and at 12 months after the operation ( $r = -0.36$ ;  $P < .006$ ).

The pregnancy rates recorded after laparoscopic stripping surgery in the 54 patients with endometriomas were as follows: seven women (13.0%) gave birth to a child before surgery; 31 (57.4%) were interested in achieving pregnancy; 17 (31.5%) were interested in achieving pregnancy at a future date; and six (11.1%) did not want children for various reasons. Of the 31 women who were interested in achieving pregnancy, 18 (58.1%) spontaneously became pregnant and gave birth to a live baby. In addition, six of those 31 women (19.3%) became pregnant by means of in vitro fertilization and had a live birth.

## DISCUSSION

The decrease in serum AMH concentrations has been suggested to occur immediately after the surgical stripping of the endometrioma and is maintained for 3, 6, and 9 months after surgery (14, 15, 19, 20, 23, 28–30). According to Celik et al., a further progressive decrease in serum AMH concentrations is possible in 24% of patients 6 weeks after surgery, reaching 67% in patients with bilateral

TABLE 2

Univariate linear regression analysis with the rate of decrease in antimüllerian hormone (AMH) levels recorded at 12 mo as the dependent variable.

Variable	B	SE	P value
AMH baseline	-2.99	2.92	.311
Age	-0.74	1.17	.530
Unilateral	-12.46	11.19	.271 <sup>b</sup>
Operation duration	-0.07	0.26	.787
AFS score	-0.26	0.22	.229
Therapy			
Contraception	-10.47	19.67	.597
Diphereline	-8.18	18.75	.664
No therapy <sup>a</sup>			

<sup>a</sup> Reference category.

<sup>b</sup> Bilateral is the reference category.

Kovačević. Serum AMH levels 12 months after surgery. *Fertil Steril* 2018.

TABLE 3

Multivariate regression analyses with antimüllerian hormone (AMH) levels measured at 6 and 12 mo as the dependent variables.

Variable	Univariate models			Multivariate model		
	B	SE	P value	B	SE	P value
AMH baseline	0.29	0.06	< .001	0.24	0.06	< .001
Age	-0.06	0.03	.039	-0.03	0.03	.261
Unilateral endometrioma	0.64	0.27	.022	0.43	0.24	.077 <sup>b</sup>
Operation duration	<0.01	0.01	.995			
AFS score	-0.01	0.01	.358			
Therapy						
Contraception	-0.58	0.49	.235			
Diphereline	-0.44	0.46	.343			
No therapy <sup>a</sup>						

Note: AFS = american fertility society.

<sup>a</sup> Reference category.

<sup>b</sup> Bilateral is the reference category.

Kovačević. Serum AMH levels 12 months after surgery. *Fertil Steril* 2018.

endometriomas and 57% in patients with unilateral endometriomas 6 months after surgery (16). Furthermore, a study by Ercan et al. did not observe a significant decrease in serum AMH levels after surgical stripping of the endometrioma (24). A limited number of studies show that the damage to the ovarian reserve after cystectomy is temporary and that the ovarian reserve recovers over time. As shown in the study by Chang et al. of 13 women with endometriomas, serum AMH levels recovered up to 65% of the preoperative level 3 months after the surgery (25). In the study by Goodman et al., a significant decrease in serum AMH levels was observed 1 month after surgery (1.12 ng/mL, range 0.81–1.45 ng/mL) compared with the preoperative values (1.77 ng/mL, range 1.18–2.37 ng/mL); 6 months after surgery, partial recovery of the ovarian reserve was observed (1.41 ng/mL, range 0.97–1.85 ng/mL) (26). The number of studies that followed changes in ovarian reserve after cystectomy over a period longer than 6 months is limited. The study by Alborzi et al. reported a decrease in serum AMH levels in the first postoperative week, but a significant increase in serum AMH levels at 3 months after surgery, which was explained by a favorable healing process and the reperfusion of “surgically treated ovaries” (28). However, the authors did not show any further significant increase in serum AMH levels at 3–9 months after surgery. In the study by Vignali et al., the serum AMH level was measured 1 week and 3, 6, and 12 months after surgery, and a significant decrease in the ovarian reserve was observed (31). According to Vignali et al., complete recovery of the ovarian reserve is possible 12 months after surgery ( $4.01 \pm 3.39$  ng/mL) compared with the preoperative values ( $3.98 \pm 3.27$  ng/mL) ( $P > .05$ ). Those authors concluded that the damage to the ovarian reserve after cystectomy is temporary and that a complete recovery is possible. Sugita et al. reported a significant decrease in serum AMH levels 1 month after surgery in all study patients (32). Sugita et al. observed the recovery of serum AMH levels in nearly one-half of the patients 1 year after surgery, whereas in the other one-half of patients, the serum level of AMH continued to decrease from the first month to 1 year after surgery. To the best of our knowledge, the present study is the third to follow patients after the laparoscopic surgical stripping of endometriomas with the use of bipolar electrocoagulation for hemostasis and included the largest number of patients in these studies to date. After the first laparoscopy, treatment with contraceptive pills or GnRH analogues and a second-look laparoscopy were recommended.

Based on the results of our study, the three significant predictors of serum AMH values at 6 and 12 months after surgery are: 1) patient age; 2) baseline AMH levels; and 3) bilateral endometriomas. Younger patients had higher serum AMH levels at baseline and at 6 and 12 months after the surgery, but the percentage change in serum AMH levels was not related to patient age. Similar changes in serum AMH levels were observed for younger and for older patients. Similarly to our conclusion, Alborzi et al. found that patients aged  $>38$  years had significantly lower serum AMH levels at baseline than patients aged  $\leq 38$  years ( $1.58 \pm 2.53$  vs.

$3.97 \pm 3.5$  ng/mL;  $P = .003$ ). Furthermore, patients  $\leq 38$  years of age after surgery showed a rate of decrease in AMH levels similar to that of patients  $>38$  years of age (28). Several studies also reported a negative correlation between preoperative AMH hormone levels and patient age (30, 33, 34). Compared with patients with unilateral endometriomas, patients with bilateral endometriomas had lower serum AMH levels at baseline and at 6 and 12 months after cystectomy. This finding was confirmed in the study conducted by Hwu et al. (30) and contradicts findings from other prospective studies that reported a greater decrease in ovarian reserve after cystectomy in patients with bilateral endometriomas than in patients with a unilateral endometrioma (20, 25, 26, 33, 34). Of these three predictors of ovarian reserve, only the baseline AMH levels remained significant in the multivariate model.

One of the explanations for the loss of ovarian follicles is damage caused by the operative technique, particularly in the absence of a real plane of cleavage between the endometrioma and ovarian cortex that would facilitate stripping of the endometrioma (35). As shown in the study by Muzii et al., the ovarian tissue close to the ovarian hilum that was removed along with the endometrioma wall contains primordial, primary, and secondary follicles in 69% of cases (36). According to Roman et al., the cystectomy itself leads to a significant removal of healthy ovarian tissue, the thickness of which increases in proportion to the cyst diameter (37). The endometrioma itself also contributes to the loss of ovarian follicles (38). Maneschi et al. suggested that other factors, in addition to the simple mechanical stretching of the ovary capsule with the endometrioma, may be responsible for the reduced follicle density in the ovarian cortex surrounding the endometrioma (39). The size of the cyst correlates with the length and severity of the inflammatory reaction in a normal ovarian cortex with endometriomas.

Another explanation for the loss of ovarian follicles is the source of energy used for hemostasis. The use of a bipolar current for hemostasis in the vicinity of the ovarian hilum is accompanied by damage to the vasculature and subsequent loss of follicles (40–42). The preservation of the ovarian vasculature is critical for preserving ovarian reserve and is likely influenced by changes in the operative technique and the energy source used for hemostasis (5, 21, 22, 37, 40, 43–45).

### Pregnancy Outcomes

In the 31 women (out of 54) who desired a pregnancy, we noted a satisfactory incidence of spontaneous pregnancies, up to 57.4%, and we agree with the conclusion of the study by Ragni et al. that laparoscopic surgical stripping of the endometrioma with the use of bipolar current for hemostasis is associated with quantitative, but not qualitative, damage to the ovarian reserve (46). Our data are consistent with the results of two high-quality prospective cohort studies that reported crude spontaneous pregnancy rates of 57%–69% (moderate endometriosis) and 52%–68% (severe endometriosis) after laparoscopic surgery (47). We are

concerned that nearly 30% of patients are interested in pregnancy in the future, because the possibility of reoccurrence of endometriomas increases over time (48, 49).

Based on the results of the papers published to date, changes in the treatment of endometrioma in the future, either in the operative technique or the method used to establish hemostasis, should be expected.

## CONCLUSION

Based on the results of our study, we conclude that laparoscopic surgical stripping of endometriomas with the use of bipolar electrocoagulation for hemostasis leads to unwanted and inevitable damage to the ovarian reserve in patients with unilateral and bilateral endometriomas. The decrease in ovarian reserve occurs immediately after surgery. Significant predictors of serum AMH levels 6 and 12 months after surgery include the baseline serum AMH level, patient age, and bilateral endometriomas. These findings must be considered when treating older patients or patients with bilateral endometriomas who are interested in preserving their fertility.

**Acknowledgments:** The authors thank the staff of the General Hospital Subotica who were on duty during the study, and Dr. Goran Trajkovic, Associate Professor of Medical Statistics and Informatics (Department for Medical Statistics and Informatics, Faculty of Medicine, University of Belgrade), for statistical assistance.

## REFERENCES

- Eskenazi B, Warner ML. Epidemiology of endometriosis. *Obstet Gynecol Clin North Am* 1997;24:235–58.
- Meuleman C, Vandenabeele B, Fieuws S, Spiessens C, Timmerman D, d'Hooghe T. High prevalence of endometriosis in infertile women with normal ovulation and normospermic partners. *Fertil Steril* 2009;92:68–74.
- Johnson NP, Bagrie EM, Coomarasamy A, Bhattacharya S, Shelling AN, Jessop S, et al. Ovarian reserve tests for predicting fertility outcomes for assisted reproductive technology: the International Systematic Collaboration of Ovarian Reserve Evaluation protocol for a systematic review of ovarian reserve test accuracy. *BJOG* 2006;113:1472–80.
- Nisolle M, Donnez J. Peritoneal endometriosis, ovarian endometriosis, and adenomyotic nodules of the rectovaginal septum are three different entities. *Fertil Steril* 1997;68:585–96.
- Donnez J, Lousse JC, Jadoul P, Donnez O, Squifflet J. Laparoscopic management of endometriomas using a combined technique of excisional (cystectomy) and ablative surgery. *Fertil Steril* 2010;94:28–32.
- Hart RJ, Hickey M, Maouris P, Buckett W. Excisional surgery versus ablative surgery for ovarian endometriomata. *Cochrane Database Syst Rev* 2008: CD004992.
- Alborzi S, Ravanbakhsh R, Parsanezhad ME, Alborzi M, Alborzi S, Dehbashi S. A comparison of follicular response of ovaries to ovulation induction after laparoscopic ovarian cystectomy or fenestration and coagulation versus normal ovaries in patients with endometrioma. *Fertil Steril* 2007;88:507–9.
- Alborzi S, Momtahan M, Parsanezhad ME, Dehbashi S, Zolghadri J, Alborzi S. A prospective, randomized study comparing laparoscopic ovarian cystectomy versus fenestration and coagulation in patients with endometriomas. *Fertil Steril* 2004;82:1633–7.
- Beretta P, Franchi M, Ghezzi F, Busacca M, Zupi E, Bolis P. Randomized clinical trial of two laparoscopic treatments of endometriomas: cystectomy versus drainage and coagulation. *Fertil Steril* 1998;70:1176–80.
- van Rooij IAJ, Broekmans FJM, Scheffer GJ, Looman CWN, Habbema JDF, de Jong FH, et al. Serum antimüllerian hormone levels best reflect the reproductive decline with age in normal women with proven fertility: a longitudinal study. *Fertil Steril* 2005;83:979–87.
- te Velde ER, Pearson PL. The variability of female reproductive ageing. *Hum Reprod Update* 2002;8:141–54.
- te Velde ER, Scheffer GJ, Dorland M, Broekmans FJ, Fauser BC. Developmental and endocrine aspects of normal ovarian aging. *Mol Cell Endocrinol* 1998;145:67–73.
- la Marca A, Sighinolfi G, Radi D, Argento C, Baraldi E, Artesio AC, et al. Anti-müllerian hormone (AMH) as a predictive marker in assisted reproductive technology (ART). *Hum Reprod Update* 2010;16:113–30.
- Urman B, Alper E, Yakin K, Oktem O, Aksoy S, Alatas C, et al. Removal of unilateral endometriomas is associated with immediate and sustained reduction in ovarian reserve. *Reprod Biomed Online* 2013;27:212–6.
- Uncu G, Kasapoglu I, Ozerkan K, Seyhan A, Oral Yilmaztepe A, Ata B. Prospective assessment of the impact of endometriomas and their removal on ovarian reserve and determinants of the rate of decline in ovarian reserve. *Hum Reprod* 2013;28:2140–5.
- Celik HG, Dogan E, Okyay E, Ulukus C, Saatli B, Uysal S, et al. Effect of laparoscopic excision of endometriomas on ovarian reserve: serial changes in the serum antimüllerian hormone levels. *Fertil Steril* 2012;97:1472–8.
- Iwase A, Nakamura T, Nakahara T, Goto M, Kikkawa F. Assessment of ovarian reserve using anti-müllerian hormone levels in benign gynecologic conditions and surgical interventions: a systematic narrative review. *Reprod Biol Endocrinol* 2014;12:125.
- Pados G, Tsolakidis D, Assimakopoulos E, Athanatos D, Tartzis B. Sonographic changes after laparoscopic cystectomy compared with three-stage management in patients with ovarian endometriomas: a prospective randomized study. *Hum Reprod* 2010;25:672–7.
- Tsolakidis D, Pados G, Vavilis D, Athanatos D, Tsalikis T, Giannakou A, et al. The impact on ovarian reserve after laparoscopic ovarian cystectomy versus three-stage management in patients with endometriomas: a prospective randomized study. *Fertil Steril* 2010;94:71–7.
- Kwon SK, Kim SH, Yun SC, Kim DY, Chae HD, Kim CH, et al. Decline of serum antimüllerian hormone levels after laparoscopic ovarian cystectomy in endometrioma and other benign cysts: a prospective cohort study. *Fertil Steril* 2014;101:435–41.
- Song T, Kim WY, Lee KW, Kim KH. Effect on ovarian reserve of hemostasis by bipolar coagulation versus suture during laparoendoscopic single-site cystectomy for ovarian endometriomas. *J Minim Invasive Gynecol* 2015; 22:415–20.
- Asgari Z, Rouholamin S, Hosseini R, Sepidarkish M, Hafizi L, Javaheri A. Comparing ovarian reserve after laparoscopic excision of endometriotic cysts and hemostasis achieved either by bipolar coagulation or suturing: a randomized clinical trial. *Arch Gynecol Obstet* 2016;293:1015–22.
- Biacchiardi CP, Piane LD, Camanni M, Deltetto F, Delpiano EM, Marchino GL, et al. Laparoscopic stripping of endometriomas negatively affects ovarian follicular reserve even if performed by experienced surgeons. *Reprod Biomed Online* 2011;23:740–6.
- Ercan CM, Sakinci M, Duru NK, Alanbay I, Karasahin KE, Baser I. Antimüllerian hormone levels after laparoscopic endometrioma stripping surgery. *Gynecol Endocrinol* 2010;26:468–72.
- Chang HJ, Han SH, Lee JR, Jee BC, Lee BI, Suh CS, et al. Impact of laparoscopic cystectomy on ovarian reserve: serial changes of serum anti-müllerian hormone levels. *Fertil Steril* 2010;94:343–9.
- Goodman LR, Goldberg JM, Flyckt RL, Gupta M, Harwalker J, Falcone T. Effect of surgery on ovarian reserve in women with endometriomas, endometriosis and controls. *Am J Obstet Gynecol* 2016;215:589.e1–6.
- Hadley W. *Ggplot2: elegant graphics for data analysis*. New York: Springer-Verlag; 2009.
- Alborzi S, Keramati P, Younesi M, Samsami A, Dadras N. The impact of laparoscopic cystectomy on ovarian reserve in patients with unilateral and bilateral endometriomas. *Fertil Steril* 2014;101:427–34.
- Lee DY, Young Kim N, Jae Kim M, Yoon BK, Choi D. Effects of laparoscopic surgery on serum anti-müllerian hormone levels in reproductive-aged women with endometrioma. *Gynecol Endocrinol* 2011;27:733–6.

30. Hwu YM, Wu FS-Y, Li SH, Sun FJ, Lin MH, Lee RK-K. The impact of endometrioma and laparoscopic cystectomy on serum anti-müllerian hormone levels. *Reprod Biol Endocrinol* 2011;9:80.
31. Vignali M, Mabrouk M, Ciocca E, Alabiso G, Barbasetti di Prun A, Gentilini D, et al. Surgical excision of ovarian endometriomas: does it truly impair ovarian reserve? Long term anti-müllerian hormone (AMH) changes after surgery. *J Obstet Gynaecol Res* 2015;41:1773–8.
32. Sugita A, Iwase A, Goto M, Nakahara T, Nakamura T, Kondo M, et al. One-year follow-up of serum antimüllerian hormone levels in patients with cystectomy: are different sequential changes due to different mechanisms causing damage to the ovarian reserve? *Fertil Steril* 2013;100:516–22.e3.
33. Hirokawa W, Iwase A, Goto M, Takikawa S, Nagatomo Y, Nakahara T, et al. The post-operative decline in serum anti-müllerian hormone correlates with the bilaterality and severity of endometriosis. *Hum Reprod* 2011;26:904–10.
34. Chen Y, Pei H, Chang Y, Chen M, Wang H, Xie H, et al. The impact of endometrioma and laparoscopic cystectomy on ovarian reserve and the exploration of related factors assessed by serum anti-müllerian hormone: a prospective cohort study. *J Ovarian Res* 2014;7:108.
35. Donnez J, Nisolle M, Gillet N, Smets M, Bassil S, Casanas-Roux F. Large ovarian endometriomas. *Hum Reprod* 1996;11:641–6.
36. Muzii L, Bianchi A, Crocè C, Mancini N, Panici PB. Laparoscopic excision of ovarian cysts: is the stripping technique a tissue-sparing procedure? *Fertil Steril* 2002;77:609–14.
37. Roman H, Tarta O, Pura I, Opris I, Bourdel N, Marpeau L, et al. Direct proportional relationship between endometrioma size and ovarian parenchyma inadvertently removed during cystectomy, and its implication on the management of enlarged endometriomas. *Hum Reprod* 2010;25:1428–32.
38. Kitajima M, Defrère S, Dolmans MM, Colette S, Squifflet J, Van Langendonck A, et al. Endometriomas as a possible cause of reduced ovarian reserve in women with endometriosis. *Fertil Steril* 2011;96:685–91.
39. Maneschi F, Marasá L, Incandela S, Mazzaresse M, Zupi E. Ovarian cortex surrounding benign neoplasms: a histologic study. *Am J Obstet Gynecol* 1993;169:388–93.
40. Zaitoun MM, Zaitoun MM, El Behery MM. Comparing long term impact on ovarian reserve between laparoscopic ovarian cystectomy and open laparotomy for ovarian endometrioma. *J Ovarian Res* 2013;6:76.
41. Li CZ, Liu B, Wen ZQ, Sun Q. The impact of electrocoagulation on ovarian reserve after laparoscopic excision of ovarian cysts: a prospective clinical study of 191 patients. *Fertil Steril* 2009;92:1428–35.
42. Garcia-Velasco JA, Somigliana E. Management of endometriomas in women requiring IVF: to touch or not to touch. *Hum Reprod* 2009;24:496–501.
43. Roman H, Bubenheim M, Auber M, Marpeau L, Puscasiu L. Antimüllerian hormone level and endometrioma ablation using plasma energy. *JSL* 2014;18:e2014.
44. Roman H, Auber M, Mokdad C, Martin C, Diguët A, Marpeau L, et al. Ovarian endometrioma ablation using plasma energy versus cystectomy: a step toward better preservation of the ovarian parenchyma in women wishing to conceive. *Fertil Steril* 2011;96:1396–400.
45. Takashima A, Takeshita N, Otaka K, Kinoshita T. Effects of bipolar electrocoagulation versus suture after laparoscopic excision of ovarian endometrioma on the ovarian reserve and outcome of in vitro fertilization. *J Obstet Gynaecol Res* 2013;39:1246–52.
46. Ragni G, Somigliana E, Benedetti F, Paffoni A, Vegetti W, Restelli L, et al. Damage to ovarian reserve associated with laparoscopic excision of endometriomas: a quantitative rather than a qualitative injury. *Am J Obstet Gynecol* 2005;193:1908–14.
47. Dunselman GAJ, Vermeulen N, Becker C, Calhaz-Jorge C, d'Hooghe T, de Bie B, et al. ESHRE guideline: management of women with endometriosis. *Hum Reprod* 2014;29:400–12.
48. Carmona F, Martínez-Zamora MA, Rabanal A, Martínez-Román S, Balasch J. Ovarian cystectomy versus laser vaporization in the treatment of ovarian endometriomas: a randomized clinical trial with a five-year follow-up. *Fertil Steril* 2011;96:251–4.
49. Kim ML, Kim JM, Seong SJ, Lee SY, Han M, Cho YJ. Recurrence of ovarian endometrioma after second-line, conservative, laparoscopic cyst enucleation. *Am J Obstet Gynecol* 2014;210:216.e1–6.

### **Cambios en los niveles séricos de hormona antimülleriana en pacientes 6 y 12 meses después de la cirugía para eliminar endometrioma**

**Objetivo:** Investigar el impacto de la quistectomía laparoscópica del endometrioma sobre la reserva ovárica, e identificar los factores más importantes para predecir la reserva ovárica en pacientes con endometrioma

**Diseño:** Estudio prospectivo.

**Lugar:** Unidad endoscopia de un hospital general

**Pacientes:** Cincuenta y cuatro pacientes con endometrioma unilateral (n=37) y bilateral (n=17)

**Intervención:** Concentración sérica de hormona antimülleriana (AMH) antes de la cirugía y 6 y 12 meses después.

**Medida principal:** la medida principal fue el daño sobre la reserva ovárica medido como concentración de AMH en suero. Las medidas secundarias fueron la persistencia o recuperación del daño ovárico 1 año después.

**Resultados:** Las concentraciones de AMH descendieron tras la escisión laparoscópica de los quistes de endometrioma ováricos. Antes de la cirugía, y a los 6 y 12 meses tras la cirugía, las concentraciones fueron 3.07, 1.29, and 1.46 ng/mL, respectivamente. En el grupo unilateral, la mediana para los niveles de AMH fue 3.31, 1.43, and 1.72 ng/mL, mientras que en el grupo bilateral los niveles fueron 2.55, 0.98, and 0.89 ng/mL. La concentración sérica de AMH descendió un  $53.27 \pm 38.2\%$  y  $49.43 \pm 38.3\%$  a los 6 y 12 meses, respectivamente tras la quistectomía.

**Conclusión:** En pacientes con endometriomas, el descenso de la reserva ovárica ocurre inmediatamente después de la escisión del endometrioma. Los predictores significativos para los valores de AMH a los 6 y 12 meses, incluyen el nivel basal de AMH, la edad de la paciente, y el endometrioma bilateral.